

Cover image

The letter pi on the ankle *La letra pi en el tobillo*

S. Hortelano Marco¹, R. Navarro Mont¹, I. Guillén Vicente²

¹ Foot and Ankle Unit. Clínica CEMTRO. Madrid (Spain)

² Cartilage Unit. Clínica CEMTRO. Madrid (Spain)

Correspondence:

Dr. Sergio Hortelano Marco

E-mail: sergio.hortelano@clinicacentro.com

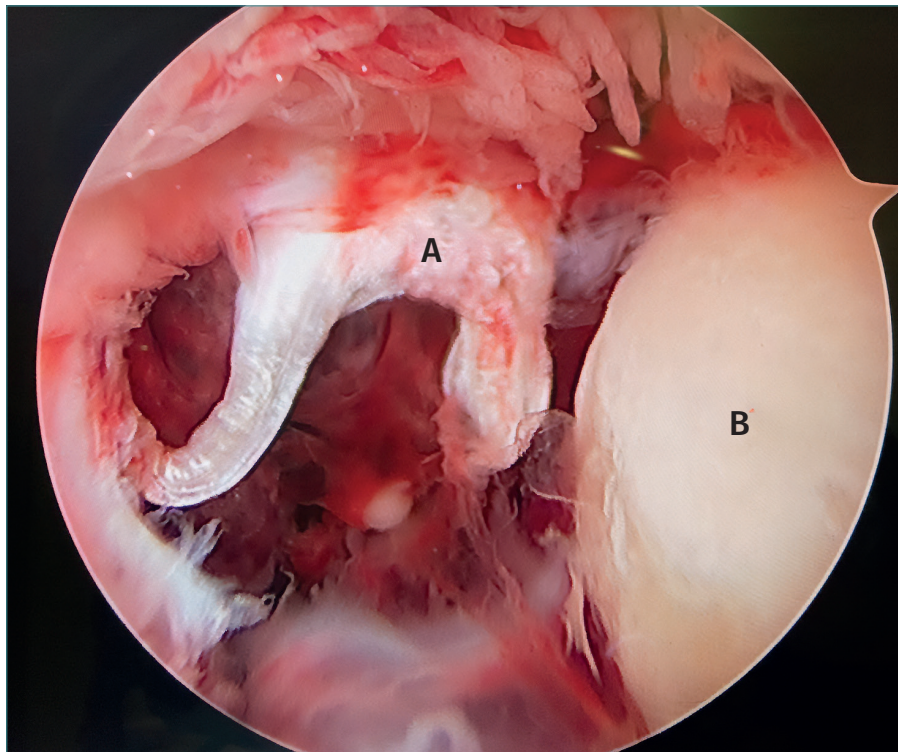
Received 29 January 2023

Accepted 01 November 2025

Available online: November 2025

Anterior ankle arthroscopy in a patient with a Maisonneuve fracture (fracture of the posterior malleolus, fracture of the neck of the fibula, anterior tibiofibular ligament tear and syndesmosis).

The letter A shows the tear of the anteroinferior tibi-ofibular ligament or Bassett's ligament, which takes on a shape similar to that of the letter pi. The talus is identified by the letter B.



<https://doi.org/10.24129/j.reacae.32284.fs2301007>

© 2025 Fundación Española de Artroscopia. Published by Imaidea Interactiva in FONDOSCIENCE® (www.fondoscience.com). This is an Open Access article under license CC BY-NC-ND (www.creativecommons.org/licenses/by-nc-nd/4.0/).