



Cover image

## Two handles to grasp: double bucket-handle meniscal lesion

### *Dos asas que asir: doble lesión meniscal en asa de cubo*

I.J. Cebreiro Martínez-Val<sup>1,2</sup>, P. Crespo Hernández<sup>1</sup>

<sup>1</sup> Hospital Universitario Ramón y Cajal. Madrid (Spain)

<sup>2</sup> Hospital Universitario HM Sanchinarro. Madrid (Spain)

**Correspondence:**

Dr. Ignacio J. Cebreiro Martínez-Val

E-mail: icebreiro@hotmail.com

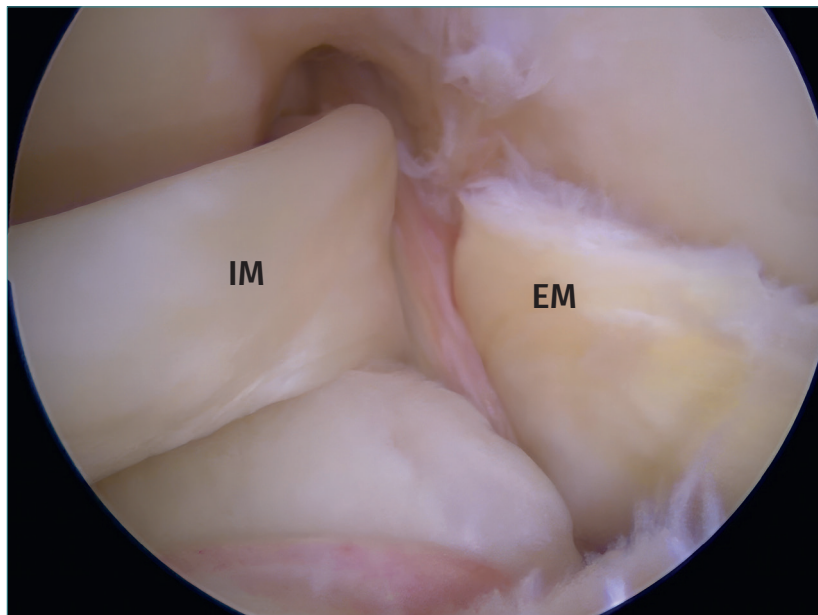
Received 2 November 2024

Accepted 15 December 2024

Available online: December 2024

A double bucket-handle tear of the meniscus of the knee is a serious injury, though fortunately it is very rare. Sometimes the patient has suffered one of the meniscal injuries for months accompanied by an unstable knee, which favors occurrence of the second injury in a new accident. In this case, the patient had suffered a partial anterior

cruciate ligament tear associated to a bucket-handle injury of the internal meniscus that had not been correctly diagnosed. In a subsequent trauma episode he developed the external meniscus injury. As this was a young patient, both menisci and the ligament were repaired at surgery, with good results.



<https://doi.org/10.24129/j.reacae.31282.fs2411024>

© 2024 Fundación Española de Artroscopia. Published by Imaidea Interactiva in FONDOSCIENCE® ([www.fondoscience.com](http://www.fondoscience.com)). This is an Open Access article under license CC BY-NC-ND ([www.creativecommons.org/licenses/by-nc-nd/4.0/](http://www.creativecommons.org/licenses/by-nc-nd/4.0/)).